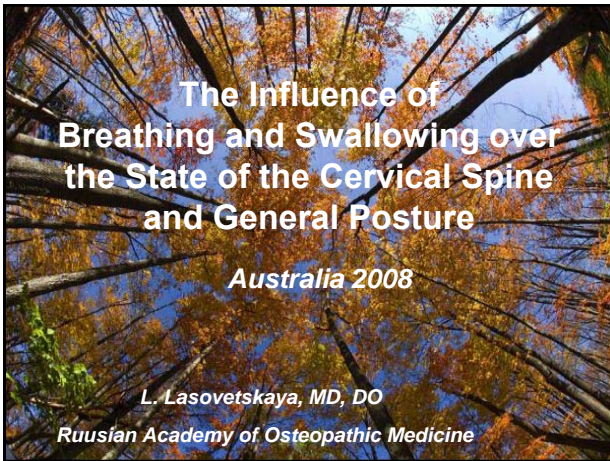

Our posture is the result of interaction of two counter-directed forces.

- On the one hand, we are under the compressing influence of gravitational forces (the descending component).
- On the other hand, the force of gravity is resisted by connective tissue or body stroma due to their elastic and resistant characteristics (the ascending component).

- The resistance coming from our body consists of many rhythms existing in it.
- That's why minor regular movements, their amplitude, their main vector, frequency and phases should be of great interest for osteopaths.

Breathing.

- We make for about 14–20 breathing excursions per minute or over 20,000 per 24 hours.
- It means that during this time there are over 20,000 rhythmic cycles of pressure and volume changes in the nasal passages, air sinuses, airways, thoracic and abdominal cavity; and the wave created by this rhythm pervades all body structures.

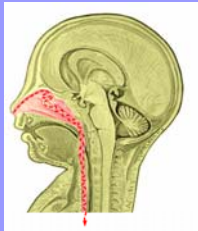Breathing is traditionally classified into

- thoracic,
- abdominal and
- mixed types,
- female and
- male types, etc.

But it will be more appropriate to talk about correct and faulty or incorrect breathing patterns.

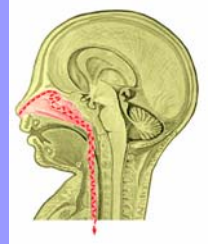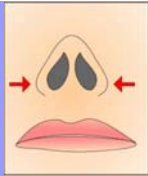Normally during in-breath the air should predominantly flow along the inferior and partly median nasal passage, which allows it to preserve its laminar flow, to go freely into the nasopharynx and further on – into the bronchial-pulmonary system.

With this action the nostrils should widen during in-breath.



The other type of breathing may be called a **sniffing pattern**.

With this type of breathing the nostrils narrow during in-breath, and the air is predominantly directed into the **superior** nasal passage, where the olfactory receptor apparatus is located



If this type of breathing is in constant use it may be logical to suppose that prolong stimulation of receptors will cause their irritation, and the flow of air along a broken line creates its further turbulence.

Under these conditions hyper-stimulation of the nasal receptor apparatus and turbulent air flow may be regarded as factors provoking prolonged colds.

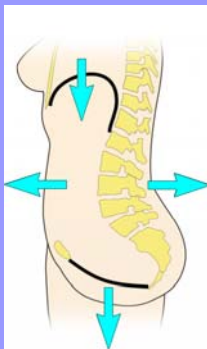- In Saint Petersburg we evaluated random gatherings of various people of different age, and found out that 40% or even 50% of them were constantly using this sniffing type of nasal breathing.

- Out of their number up to 90% suffered with prolonged seasonal rhinitis, and approximately 30% complained of constant torpid colds or vasomotor rhinitis.

According to Rollin Becker and Robert Fulford any rhythmic motion existing in the body should freely permeate all its tissues.

Under these conditions the body can function with minimal energy demands, and preserve the optimal health level.

Breathing is the only constantly present rhythmic motion of the body, which is amendable to voluntary temporary changes of its rate and depth.



Let's see what's happening in the area beneath the diaphragm in quiet diaphragmatic breathing.

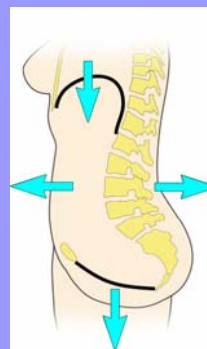
In in-breath

- the diaphragm contracts,
- lumbar lordosis decreases,
- the anterior abdominal wall moves forward, and
- the pelvic floor descends.

During out-breath

- the diaphragm becomes relaxed,
- lumbar lordosis increases,
- the lumbar spine and the anterior abdominal wall became approximated
- the pelvic floor ascends.

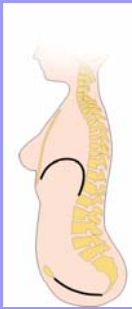
← inhalation
→ exhalation



It provides for rhythmic pressure changes in the abdominal cavity necessary for adequate venous and lymphatic return.

← inhalation
→ exhalation

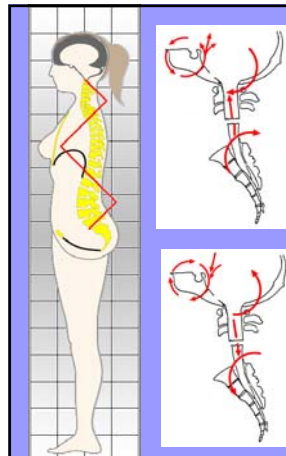
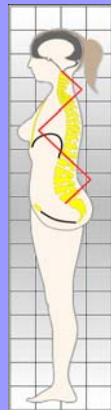
The thoracic spine.



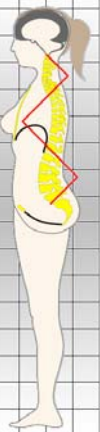- although the chest becomes wider the thoracic kyphosis is going to flatten.

- It's difficult to see clearly how cervical lordosis flattens in in-breath.
- But if you position a person supine, and start palpating the cervical spine in quiet breathing you will be able to feel its flattening actually at the level of motility.

- We may compare this movement with a spring:
- during in-breath (the active part of movement) the spring is compressed,
- during out-breath (the passive part of movement) it straightens by itself.



- It's interesting to note that breathing wave propagation coincides with the direction of the propagation of the primary respiratory impulse.

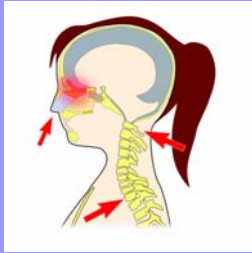


- Namely during in-breath the spine becomes shorter, wider and straighter.
- During out-breath the reverse happens.
- Don't you think that the waves created by correct breathing represent the mechanism, which has been given to human beings by the Great Architect for them to be able to "wash away" existing dysfunctions?

Incorrect or sniffing breathing pattern.

To be able to understand it better try to reproduce this movement.

Start inhaling as if you are sniffing and observe the movement of your cervical spine, CD junction and chest.

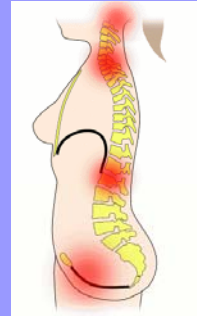


Incorrect or sniffing breathing pattern.

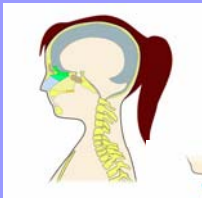
To be able to understand it better try to reproduce this movement.

Start inhaling as if you are sniffing and observe the movement of your cervical spine, CD junction and chest.

Those of you who are accustomed to normal breathing will immediately feel which areas are under compression.

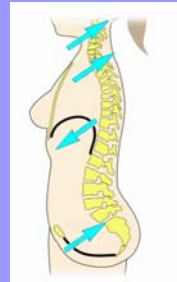
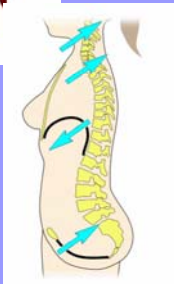


- Now think of over 20,000 of incorrect breathing movements done during 24 hours, and you'll understand that with this pattern the mechanism, which has been designed by the Great Master to help us, turns into a highly traumatic process.



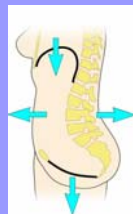
- In people with the sniffing breathing pattern the whole of the spine is subjected to shearing forces.

- We will find
- C0 – C1 compression,
 - CD and
 - DL dysfunction.

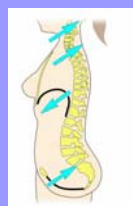

- If a person with this pattern tries to use abdominal breathing real diaphragmatic flattening will not happen.
- Although the anterior abdominal wall moves forward, as it should happen in breathing through the widened nostrils, the epigastric area is sucked inside, and lumbar lordosis increases.
- It means that the lumbar spine as well as the anterior abdominal wall move anteriorly.

- In this way there will be no rhythmical shape and volume changes, and because of that adequate changes in pressure gradient will not happen.



normal



abnormal

- If you watch deep breathing in people who are constantly using the sniffing pattern you'll see that they recruit their superior ribs at a very early stage, which contributes to functional shortening of cervical lordosis.
- Due to it instead of a beautiful springing movement we'll see disharmony

Causes of incorrect breathing pattern

Of course, there may be genetic peculiarities in the structure of the nose and nasopharynx

But our studies of posture done on more than 1000 of people and of movement of different spinal areas in inspiration and expiration in people with the normal and sniffing breathing patterns revealed some structural regularities.

We found the sniffing breathing pattern under the following circumstances:

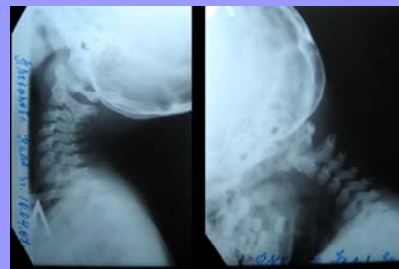- In all cases of persistent C0 – C1 compression accompanied by a dysfunction of the sphenoid-vomer articulation. This pattern in its pure form is mainly inherent to children and is usually connected with a birth trauma.
- In all patients with swallowing disturbances, especially combined with bite deformities.
- More rarely it follows a whiplash injury with its sharing forces acting over the CD and DL junctions.

The first scenario is based on the study of 310 children suffering with chronic adenoiditis.

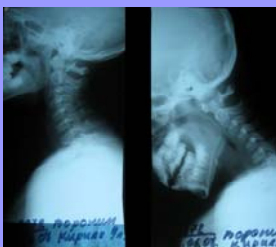- All of them used the sniffing breathing pattern and had aggravated perinatal anamnesis.

In 100% of cases osteopathic examination demonstrated

- C0 – C1 compression,
 - absence of nodding movement at this level,
 - translation of the whole segment anteriorly,
 - compensatory hyper-mobility in C1 – C2 segment in flexion.
- Nearly in half of these children these lesions were combined with intraosseous compression of the occiput.

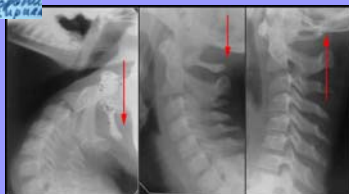

- The radiographic picture was typical.
- In functional X-rays made with the neck in flexion the distance between the posterior tubercle of the atlas and the spinous process of C2 was longer than it should be.

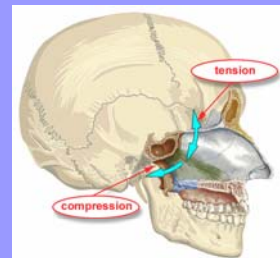


- The distance between the posterior tubercle of the atlas and the occiput did not considerably increase, and sometimes even decreased.


- Thus, disturbed nasal breathing was accompanied by the typical pattern with obligatory involvement of C0 – C1 – C2 area.



In the facial pattern there was a lesion in the sphenoid-vomer articulation with consistent displacement of the vomer to the back.



- The latter was interpreted as one of the causes of disturbed biomechanics of the ethmoid, as well as of compensatory flattening and narrowing of the nasal passages, especially of the inferior one



The present study allowed us to propose a working hypothesis about

- the primary lesion of C0 – C1 spinal segment with
- compensatory involvement of the facial structures and
- in particular of the articulation between the vomer and the sphenoid.
- The latter in its turn leads to a disturbed breathing pattern and insufficient inferior passage utilization.

The initiation of sniffing pattern, and the factors, which may influence it.

The first movement performed by the baby during labor is flexion.

With this movement the chin should nearly touch the neck as if in extreme nodding.

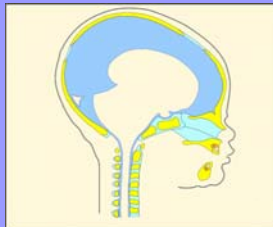
It is the only kind of engagement, which allows the head to enter the birth canal with its minimal size.

- But there are occasions, when this kind of engagement does not happen, and instead of the described movement of nodding the head is shifted forward with elements of extension.

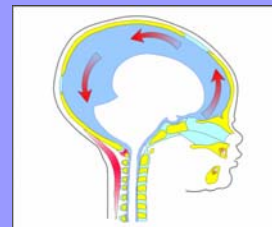
After birth it will manifest in marked

- C0 - C1 compression with the predominant involvement of the right or left side (depending upon torsion patterns present in the body of the mother and the baby), and
- compensatory hyper-mobility in C1 – C2 segment in flexion.

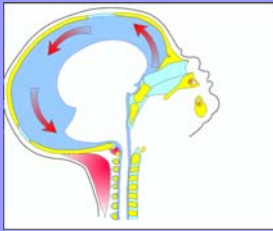
- The described situations may be caused, for example, by cord encirclement around the neck, if this loop (tense or loose) occupies the space under the chin preventing correct head flexion.
- Another cause may consist in premature amniotic sac puncture, when the flow of the escaping amniotic fluid takes with it the baby's head, and engagement happens before complete head flexion.
- It should be also mentioned that in the infant's body and particularly in the vertebral column there may be stiff areas preventing optimal head flexion.
- These regions will continue expressing compression after the birth of the baby



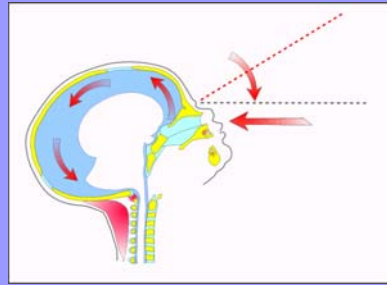
- Thus initial C0 - C1 compression primarily arising during labour leads to compensatory hyper-mobility in flexion of C1 – C2 segment.



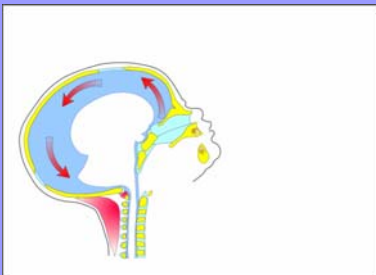
- These two factors cause protective reflex hyper-tonicity of the sub-occipital muscles holding the whole area in extension.



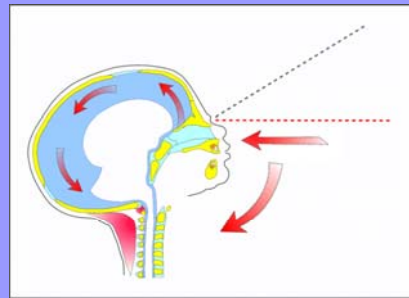
In this posture all cranial structures in the occipital sphere of influence including the frontal bone will experience a drag from behind along the direction of the falx.



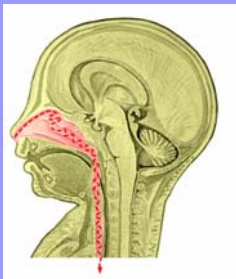
- With the development of the visual analyzer and the ability to fix the gaze, the horizontal line of vision starts forming, which gives us the ability to keep our eyes on a horizontal line especially in erect position.



- In cases of persistent C0 – C1 compression and head extension this aim may be achieved only by shifting the middle part of the face backwards, which probably happened in the articulation between the vomer and the sphenoid in our patients.



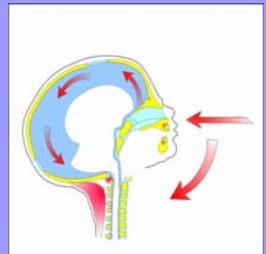
- In its turn it holds the ethmoid, which is strained between the frontal bone and the vomer. This restricts nasal bones mobility and prevents the nostrils from widening.



- ❖ Due to it the air is directed into the superior nasal passage contributing to further increase of ethmoid tension.

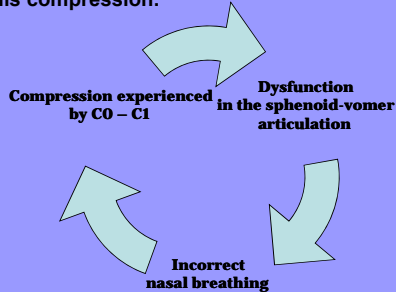
The falx is stretched and fixed between its attachments to the crista galli and the occipital foramen.

The tension experienced by the dura is an additional factor hindering normal C0 – C1 flexion and contributing to forward displacement of this restricted segment.



It manifests in instability of the anterior C1 – C2 articulation, and in some children – in decreased distance between the occiput and the first cervical vertebra in neck flexion.

- In this way a vicious circle is formed.
- Compression experienced by C0 – C1 segment potentiates dysfunction in the sphenoid-vomer articulation, and the faulty nasal breathing pattern in its turn favors this compression.



- It should be taken into consideration that although we regard this vicious circle as the primary lesion accounting for the faulty breathing pattern, prolonged usage of the latter will cause secondary lesions of the CD junction, the crura of the diaphragm, etc. creating compression areas mentioned earlier.

- These lesions although secondary may be very persistent. It means that they may not always resolve spontaneously, and without proper attention these lesions may cause faulty breathing pattern recurrence.

The disturbances of swallowing

Integration of swallowing and breathing.

- At first glance, swallowing doesn't look like a rhythmical movement because it has no return phase.
- But one should remember that it causes regular changes in the shape of the pharynx and esophagus and sends a peristaltic wave, which due to the anatomical connections between these structures involves the fascial system.
- Besides that in cases of disturbed swallowing biomechanics the accessory muscles have to start working.
- Thus it's logical to believe that swallowing disturbances will have their influence at least over the cervical spine and through it – over the general posture.

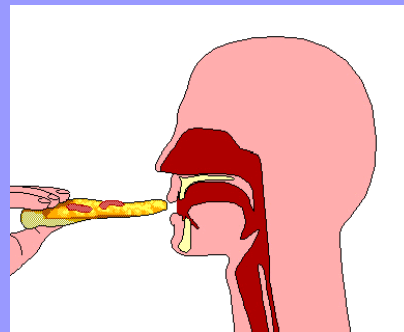
- X-rays of the cervical spine of 370 patients with osteopathically diagnosed swallowing dysfunction were studied.

- The main feature of the radiographic picture consisted in cervical lordosis flattening with peculiarities depending upon the causes of swallowing dysfunction.

How often do you see swallowing dysfunctions in your patients?

Your answer will depend upon how often you look for them.

According to our findings three out of every five patients seeking osteopathic care for disturbed or absent nasal breathing have incorrect swallowing.



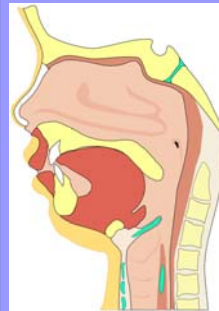- On the average we swallow 1800 times per 24 hours, twice a minute when we are awake and once a minute while sleeping (Milne H., 1995).

Two components of disturbed swallowing may be differentiated:

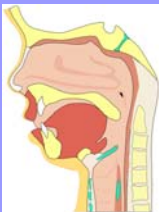- changes in the position of the tongue,
- changes in the position of the pharynx.

These two components are interrelated.

Evaluation of tongue position is an integral part of swallowing testing.

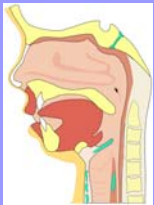

- Normally the tip of the tongue should lie against the superior border of the incisors or the anterior border of the hard palate, which is actually the same.
- At the moment of swallowing the teeth should be tightly clenched, and the back of the tongue should be tightly pressed to the hard palate.

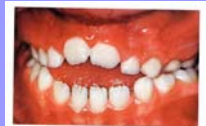

In cases of tongue dysfunction its tip may lie against

- the lower teeth or



- between the teeth.

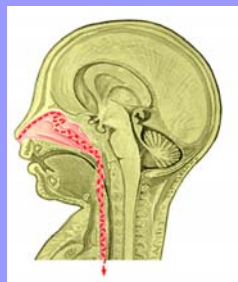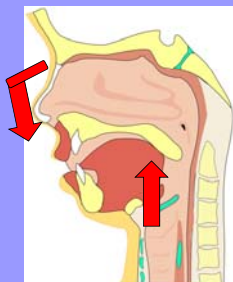


- In incorrect tongue position the mechanics of breathing has to change.

To understand that let's consider what's happening to forces when we change the position of the tongue and swallow.

- Normally the pressure on the hard palate should be uniform, which favors its widening

- If the position of the tongue is incorrect the pressure is concentrated in the posterior part of the palate.
- The nose during swallowing seems to "dive" inferiorly, which leads to its incorrect position and to narrowing of the inferior and median nasal passages



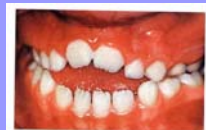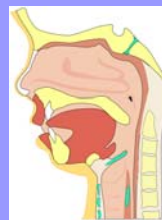Now try to press your tongue to the lower teeth and inhale two times – first widening your nostrils, and then narrowing them as if you are sniffing.

- In the first case you will feel the area of tension in the lower part of your nasopharynx, as if the air has to overcome an additional obstacle.
- If you narrow your nostrils during in-breath you won't feel this obstacle. It means that a person with an incorrect tongue position has to switch over to the sniffing type of breathing, which is more comfortable under these conditions.

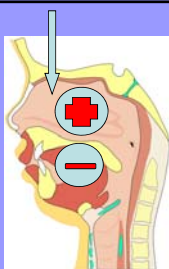
The main causes of incorrect tongue position are:

- breathing through the mouth,
- faulty habits such as thumb or lower lip sucking,
- early bottle feeding,
- short lingual frenulum,
- abnormal position of the pharynx.

Oral breathing

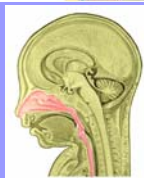

- When a child is a mouth-breather, for example because of marked hyperplasia of adenoid tissue, the tongue is positioned lower than it should be.
- That's why in swallowing its tip will lie against the lower teeth or between the teeth. The latter option is more frequent.
- It often causes secondary bite deformities
- In addition to it, permanent oral breathing creates a high "gothic" palate, which also favors an abnormal position of the tongue.



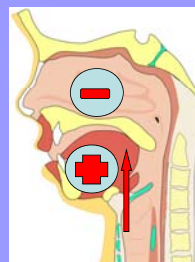
In a child the partition between the oral and nasal cavities is soft.

When breathing is happening through the nose pressure in the oral cavity regularly changes for negative, in particular when the child "sucks" and swallows saliva.



At the same time pressure in the nasal cavity created by laminar air flow is slightly positive. Thus there is a constant force acting at this partition with the vector directed downwards.

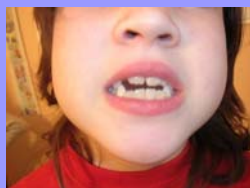- In cases of oral breathing the situation changes completely. The pressure in the nasal cavity is negative (in particular when we are sniffing), and the pressure in the oral cavity is positive. That means that the vector of force changes for the opposite one.



- Due to it in the process of growth the palate changes its shape, arching superiorly. This deformity in its turn favors oral breathing. It leads to the stage of mutual aggravation.
- In this way people who were predominantly mouth-breathers in their childhood still have problems with nasal breathing becoming adults.



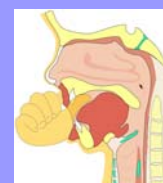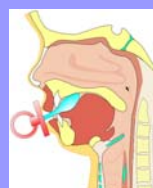Faulty habits



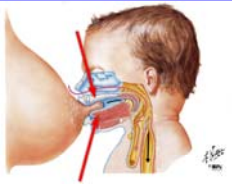
- According to literature faulty habits may be found in 80% of children with bite deformities.

- to distorted teeth formation (centered around the object, which the baby is sucking),
- to incorrect position of the tongue (which is pressed into the floor of the oral cavity) and
- to a faulty position of the pharynx.

If the habit persists the pharynx cannot develop properly and assume its proper adult position



Early bottle feeding



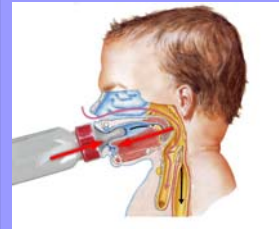
In which way is breast sucking achieved?

The milk is provided through peristaltic movements of the baby's tongue.

The nipple lies at the level of the soft palate.

The baby opens its mouth widely, grasps as much of the breast as possible, and with its tongue strains milk off, squeezes it out of the breast, pressing the nipple to the palate with the tongue.

All the groups of facial muscles participate in the process of breast sucking.



In cases of bottle feeding the process of sucking is based on pressure differences.

The only muscles, which have to work, are buccal muscles.

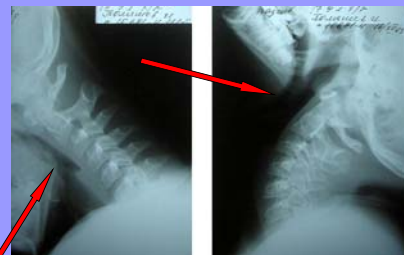- The baby performs a drawing-in movement, and milk comes flowing non-interruptedly.
- With bottle feeding the tongue moves in a different way – anteriorly and posteriorly.

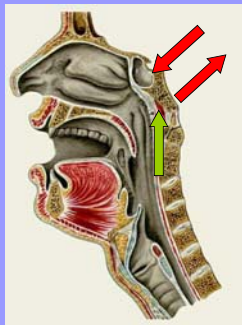
- Abnormal tongue position is not infrequently seen in cases of short tongue frenulum, limiting its mobility.
- Under this condition the tongue is simply unable to assume its normal position. It may cause open bite deformity.

- The position of the tongue may depend upon the position of the pharynx.
- We can differentiate two kinds of its mechanical and positional disturbances.

- The first type is concerned with positional changes caused by changes in the position of adjacent structures.
- The pharynx possesses its own muscular apparatus, and topographically lies very close to the cervical area of the spine.
- It contains neither osseous nor chondral structures, which might help it to preserve its shape.
- Due to this its shape will depend only upon the space provided by surrounding hard structures – the cervical spine posteriorly and the larynx anteriorly at its transition into the esophagus.

- According to Frank Willard during flexion of the cervical spine the space provided for the pharynx decreases, during extension it increases.
- That's why people with swallowing problems throw their head back.

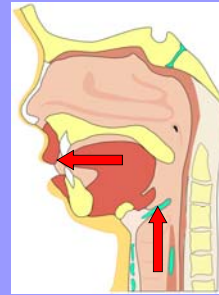




Retardation of pharynx development may be due to an inferior vertical strain of the cranial base

In the presence of this strain the base of the occiput lies higher than the base of the sphenoid, and the pharynx is “suspended” on its posterior attachment (to the pharyngeal tubercle of the occiput).

The base of the sphenoid is lower, the pterygoid processes are superior and medially, which creates an additional tension experienced by the anterior fascial sheaths covering the pharynx.



The third group of causes includes any kind of incorrect tongue position.

We touched upon it earlier talking about the tongue. In this case the tongue assumes a relatively anterior position and drags the pharynx superiorly.

Let's experiment once again. Position your tongue between your teeth and try to swallow. You will immediately feel that the pharynx is being dragged superiorly.

- The fourth group includes cases of retarded pharynx descent due to “retarded descent” of the whole mediastinum.
- According to professor Willard's classification the fascia surrounding the pharynx is a part of the integral visceral sheath.
- That's why any tension existing below the pharynx will influence its development.

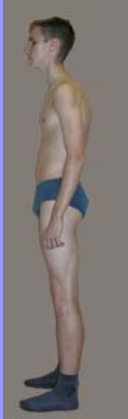- As you know, in an embryo the heart and all the tissues of the mediastinum are situated very high, actually under the chin.
- In the process of their development they descend assuming their final position only with the cessation of growth.
- That's why if this process becomes affected it will influence the development of the pharynx.
- For example, our findings show that if the mother experiences an emotional stress during pregnancy the embryo will also experience it. This may lead to formation of an area of restriction, usually in mediastinal fascias.

The next cause consists in umbilical cord encirclement around the neck during the process of birth.

- This leads to a direct injury of the anterior throat structures and increased flow of afferent impulses with possible facilitation of the corresponding stem nuclei, influencing the muscle tone.
- On the other hand, the cord wrapped around the neck will prevent the baby's head from normal flexion during delivery, causing flexion below this loop.

And now the last cause.

- If the pharynx experiences a prolonged compression due to a somatic dysfunction of the cervical spine its growth is going to be retarded.
- In this case it will be smaller than the growing spine and the tongue, and abnormal swallowing will persist



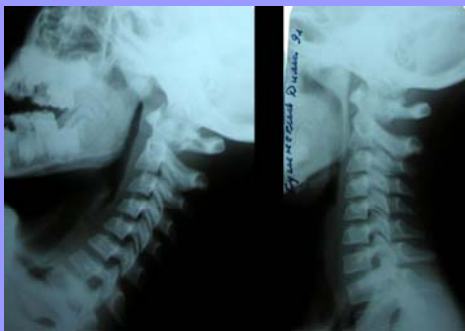- People with incorrect breathing demonstrate C0 – C1 compression, CD junction kyphosis, faulty movement of the diaphragm.
- Now let's add to this picture head protrusion as if someone were pulling on the tongue of this person, extend this tension over to the mediastinum, and you'll have the typical picture of a young man with his head thrust forward, raised shoulders and hollow chest.
- Of course, there may be some variations depending upon the origin of the pattern, but on the whole the picture is quite typical.

As it has been already mentioned X-rays of the cervical spine in cases of swallowing problems always demonstrate a flattened curve

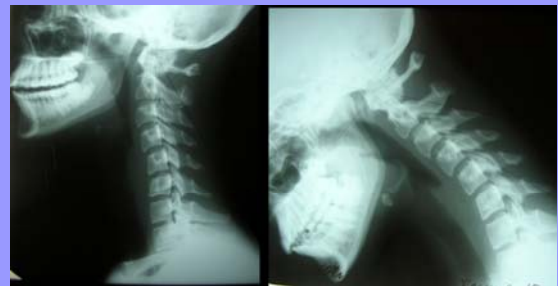Basing on a radiographic picture we may differentiate two main variants – structural and functional.

In the former the somatic dysfunction of the cervical spine is primary, and the latter is caused by the primary tension along the soft tissues of the pharynx and the anterior throat.

In the first case lateral functional X-rays will show an interruption of the cervical curve at the dysfunction level, in the second case the cervical region becomes universally kyphotic like the string of a bow.



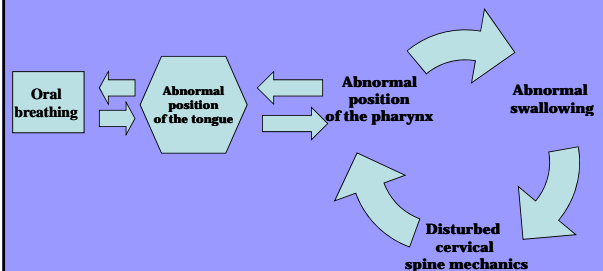
- Functional type



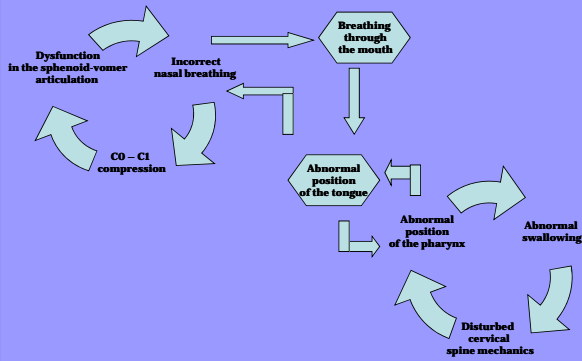
- Traumatic type

- Thus according to the aforesaid all swallowing dysfunctions are caused by changes in the position of the pharynx due to disturbances of cervical spine mechanics, problems with pharynx development and tongue dysfunctions. In its turn it may cause restriction of cervical spine extension, affect tongue mechanics and nasal breathing.

A simple pattern of incorrect swallowing formation



Interaction of the two patterns

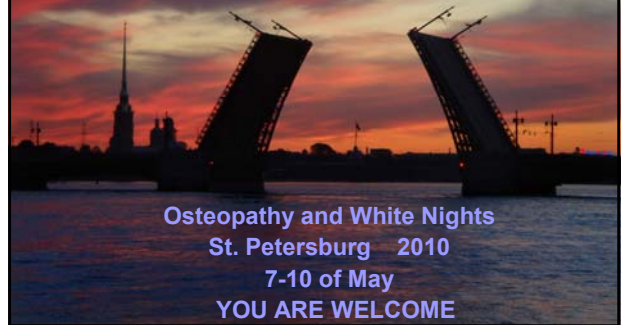

- In this way a self-perpetuating pattern is formed; it progresses with the child's development and leads to postural defects.
- To deal with this situation we first of all have to normalize the breathing pattern, to restore the normal mechanics of the palate and the tongue and to work with the whole cervical spine.



Thank you for your attention

Osteopathic conference



Osteopathy and White Nights
St. Petersburg 2010
7-10 of May
YOU ARE WELCOME